

Bilateral Transversus Abdominis Plane Nerve Blocks for Analgesia Following Cesarean Delivery: Report of 2 Cases

John D. Scharine, CRNA, MSNA, APNP

These 2 case reports describe the use of transversus abdominis plane (TAP) nerve blocks for analgesia following emergency cesarean delivery. Bilateral single shot TAP blocks provided prolonged and extremely effective analgesia. Patients displayed early oral intake, early ambulation, and low pain scores. No postopera-

tive narcotics were used by either patient throughout their hospital stay. A technique for TAP blocks is described with discussion of risks and suggested uses.

Keywords: Nerve block, transversus abdominis plane nerve block, TAP nerve block.

One goal of perioperative anesthesia care is effective postoperative analgesia. Inadequately treated postoperative pain following abdominal surgery causes several negative effects (Table 1).¹

Postoperative pain is often treated with systemic or neuraxial opioids. Treatment with opioids creates the need for increased action and monitoring by staff, frequently requires cumbersome equipment in the form of pumps or monitors, and causes additional undesirable side effects (Table 2).² Even the commonly used patient controlled intravenous analgesia (PCA) is not without risks. Overdyk et al³ recently reported in their group of 178 patients receiving meperidine or morphine PCA that 12% experienced desaturation ($SpO_2 < 90\%$) and 41% experienced bradypnea (respiratory rate $< 10/\text{min}$) of 3 minutes or longer duration. Use of opioids and their subsequent side effects can be reduced or eliminated by application of regional anesthesia with local anesthetics.

In February 2007, my anesthesia group began using the transversus abdominis plane (TAP) nerve blocks for postoperative analgesia as described by McDonnell et al.⁵ That description reports the use of TAP blocks for bowel resections. In that series, TAP blocks reduced the first 24-hour postoperative morphine consumption by more than 70% and more than halved the incidence of nausea from 69% to 31%. A previous report has described the use of TAP blocks for abdominal prostatectomy.⁵ We subsequently applied TAP blocks to a variety of abdominal cases including ventral and incisional hernia repairs and routinely to all cesarean deliveries.

In July 2007, I TAP blocked 2 patients following emergency cesarean deliveries that had been performed under general anesthesia. These emergency situations required general anesthesia that precluded the use of neuroaxial narcotics for postoperative analgesia. This presented the opportunity to retrospectively evaluate the effectiveness

Splinting, hypoventilation, and atelectasis
Immobility, hypercoagulability, and thromboembolic events
Vasoconstriction, tachycardia, increased systemic vascular resistance, dysrhythmias, and cardiac ischemia in susceptible patients
Insomnia, anxiety, feeling of helplessness

Table 1. Postoperative Abdominal Pain Effects
(Adapted from Lubenow et al.¹)

Respiratory depression
Drowsiness, sedation
Nausea and vomiting
Urinary retention
Constipation
Ileus
Pruritus

Table 2. Opioid Side Effects
(Adapted from White.²)

of TAP blocks in cesarean delivery patients as the key component of postoperative analgesia without neuroaxial narcotics.

Case Summaries

• *Case 1.* A 33-year-old parturient, 165 cm, 82 kg, gravida 1, and 40^{3/7} weeks' gestation presented to the operating room emergently due to sustained fetal heart rates (FHR) of 90 to 100/min. The patient was positioned with left uterine displacement, 100% oxygen was given, and monitors were applied. During rapid-sequence induction, she was given propofol, 150 mg; lidocaine, 75 mg; and succinylcholine, 120 mg. Sevoflurane, 0.6%, was begun.

Following delivery of the infant, anesthesia was deepened with midazolam, 2 mg; fentanyl, 400 µg; and the volatile agent was increased. Oxytocin, 10 U intravenous

	Pain score 1-10 scale	Aldrete score 1-10 scale
Patient 1		
Admission	0	9
15 min	0	9
30 min	0	10
45 min	0.5	10
Discharged to floor		
Patient 2		
Admission	0	9
15 min	0	9
30 min	0	10
45 min	0	10
Discharged to floor		

Table 3. Patient Pain and Aldrete Scores in Postanesthesia Care Unit

Pain score: 0, no pain; 10, worst imaginable pain.

(IV) push; cefoxitin, 2 g; metoclopramide, 10 mg; ranitidine, 50 mg; and ondansetron, 4 mg, were administered. Oxytocin, 20 U/L, was added to the IV fluid. At the end of the case, ketorolac, 30 mg IV, was given. The patient was extubated awake and taken to the postanesthesia care unit (PACU). Following local anesthesia with 1 to 2 mL 1% plain lidocaine, bilateral TAP blocks were administered using 0.5% bupivacaine with epinephrine, 20 mL per side.

Postoperative analgesia orders were for acetaminophen, 650 mg every 4 hours when necessary, ibuprofen, 600 mg every 4 hours when necessary, hydrocodone with acetaminophen, 5/500, 1 to 2 tablets every 6 hours when necessary, and morphine PCA when necessary.

- *Case 2.* A 21-year-old parturient, 157 cm, 68 kg, gravida 2, para 1, and 33⁵/₇ weeks' gestation presented to the operating room emergently because of complete cervical dilatation with breech presentation. Left uterine displacement, 100% oxygen, and monitors were applied. During rapid-sequence induction, she was given propofol, 150 mg; lidocaine, 75 mg; and succinylcholine, 120 mg. Sevoflurane, 0.5%, was begun.

Following delivery of the infant, anesthesia was deepened with midazolam, 2 mg; fentanyl, 400 µg; ketamine, 20 mg; 50% nitrous oxide; and the volatile agent was changed to desflurane. Oxytocin, 10 units IV push; cefoxitin, 2 g; metoclopramide, 10 mg; ranitidine, 50 mg; and ondansetron, 4 mg; were administered. Oxytocin, 20 U/L, was added to the IV fluid. At the end of surgery she was given ketorolac, 30 mg IV. While emerging from anesthesia in the operating room, bilateral TAP blocks were administered using 0.5% bupivacaine with epinephrine, 20 mL per side. The patient was extubated awake and taken to the PACU.

Postoperative analgesia orders were for ketorolac, 30

Time	Pain score	Scheduled analgesic (mg IV)	PRN analgesic (mg PO)
Patient 1			
POD #1			
12:30 AM	0.5		
admit to unit			
1:40	0.5		
6:00	1		
8:10	0		
11:00	3		APAP, 650
Noon	1		
3:30 PM	3		APAP, 650
4:10	1		
10:00	1		APAP, 650
POD #2			
2:45 AM	1		
6:35	2		Ibuprofen, 600
7:30	1-2		
3:30 PM	3		Ibuprofen, 600
10:30	4		Ibuprofen, 600
POD #3			
4:15 AM	2		Ibuprofen, 600
10:00	1-2		Ibuprofen, 600
4:00 PM	1-2		Ibuprofen, 600
10:00	1-2		Ibuprofen, 600
POD #4			
5:00 AM	1-2		Ibuprofen, 600
discharged			
Patient #2			
DOS			
7:30 PM	0	Ketorolac, 30	
POD #1			
12:30 AM	0	Ketorolac, 30	
7:30	0	Ketorolac, 30	
3:30 PM	0	Ketorolac, 30	
9:30	0	Ketorolac, 30	
POD #2			
3:30 AM	0	Ketorolac, 30	
9:30	0	Ketorolac, 30	
11:50	0		
discharged			

Table 4. Postoperative Pain Scores and PRN Analgesics

Pain score: 0, no pain; 10, worst imaginable pain.

PO indicates postoperative; PRN, as needed; IV, intravenous; DOS, day of surgery; POD, postoperative day; APAP, acetaminophen.

mg IV every 6 hours until discharge. For breakthrough pain, acetaminophen, 650 mg every 4 hours when necessary; oxycodone with acetaminophen, 5/325, 1 to 2 tablets every 4 hours when necessary; and morphine, PCA when necessary.

Day/meal	Diet	Consumption (%)	Note
Patient 1			
POD 1			
Breakfast	Clear liquid	100	7 h PO
Lunch	Semiliquid	100	
Dinner	Semiliquid	100	
POD 2			
Breakfast	General	100	
Lunch	General	100	
Dinner	General	100	
POD 3			
Breakfast	General	100	
Lunch	General	100	
Dinner	General	100	
POD 4			
Breakfast	General	100	
Discharged			
Patient 2			
DOS			
Dinner	Clear liquid	100	5 h PO
POD 1			
Breakfast	Clear liquid	100	
Lunch	Semiliquid	100	
Dinner	General	100	
POD 2			
Breakfast	General	100	
Discharged			

Table 5. Patient Dietary Intake

DOS indicates day of surgery; POD, postoperative day; PO, postoperative.

Results

Postanesthesia care unit pain and recovery scores are listed in Table 3. Although the patients in the 2 case reports were alert and significantly recovered from anesthesia, both reported low pain scores and neither patient required any treatment for pain while in PACU.

Postpartum nursing unit pain scores and analgesic treatments are listed in Table 4. Both patients reported low pain scores and did not use any of the narcotic analgesic options available to them. The patients were up in their rooms, ambulated the unit freely, and showered on all postoperative days.

Patient dietary intake is listed in Table 5. Each patient consumed 100% of all meals, and neither had any complaints of nausea or constipation.

Block Anatomy

The muscle layers of the lateral abdominal wall progressing from external to internal are the external abdominal oblique, the internal abdominal oblique, and the transversus abdominis.⁶

The abdominal wall is innervated by divisions of spinal segmental nerves running laterally between the

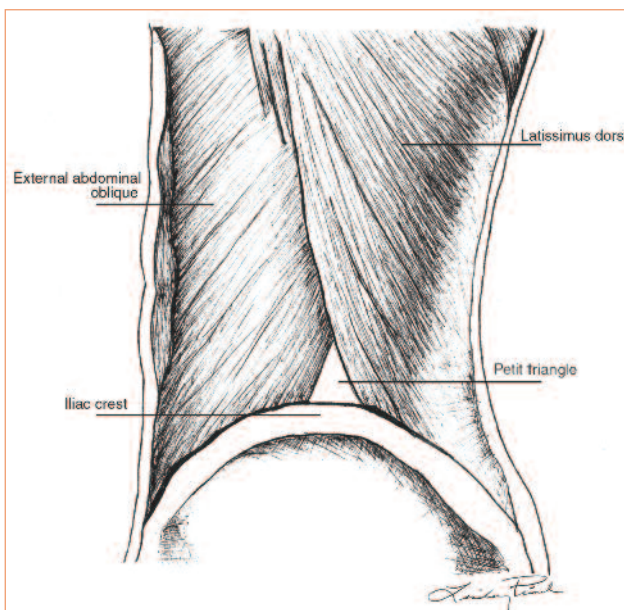


Figure 1. Lateral Abdominal Wall Showing the Lumbar Petit Triangle

The Petit triangle is bordered inferiorly by the iliac crest, posteriorly by the latissimus dorsi, and anteriorly by the external abdominal oblique.

(Illustration by Lindsey B. Pionek.)

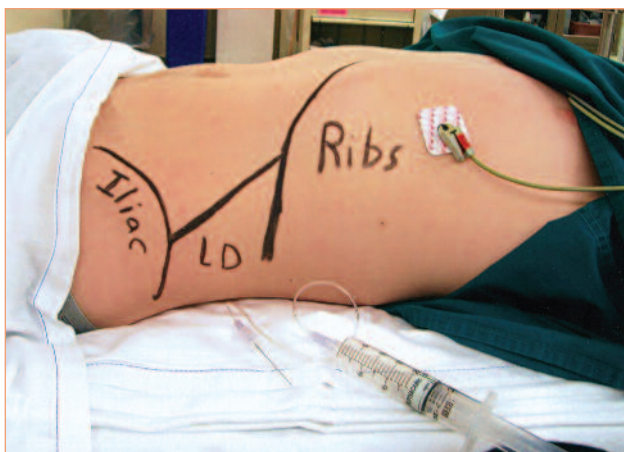


Figure 2. Method of Skin Marking to Show Key Landmarks: Iliac Crest and Latissimus Dorsi (LD)

transversus abdominis and the internal abdominal oblique.⁴ Deposition of local anesthetic in this neurofascial plane provides sensory block to the entire abdominal wall including skin, subcutaneous tissue, muscle, and parietal peritoneum from approximately T7 to L1.

The Petit triangle, which lies approximately in the mid-axillary line at the superior margin of the iliac crest, provides a palpable location to access this plain. The Petit triangle is bordered inferiorly by the iliac crest, posteriorly by the latissimus dorsi, and anteriorly by the external abdominal oblique (Figure 1 and Figure 2). Fascial extensions of the external abdominal oblique, internal oblique, and

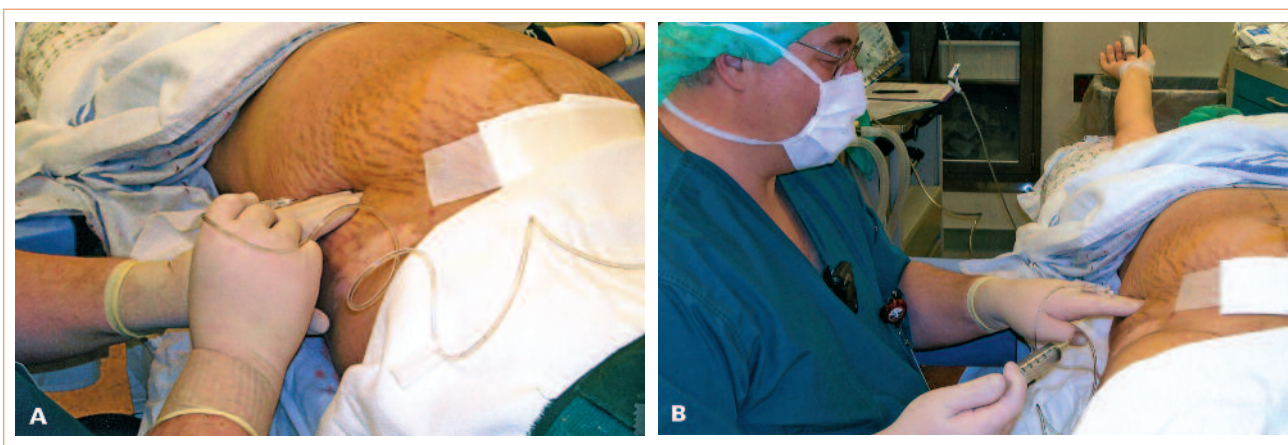


Figure 3. Patient Receiving Transversus Abdominis Plane Block in Operating Room Following Cesarean Delivery
A: Note ipsilateral arm is raised to accentuate the latissimus dorsi. Nondominant hand is on iliac crest at border of latissimus dorsi, delineating the Petit triangle. **B:** Incremental injection of local anesthetic.

transversus abdominis muscles extend across the triangle and provide characteristic pop sensations as a block needle is advanced.

Technique

This is a high volume local anesthetic block. Local anesthetic dose is calculated not to exceed 3 mg/kg or a total of 225 mg bupivacaine. Whenever possible we seek to use 0.5% bupivacaine or 0.5% ropivacaine, each with epinephrine. A lower concentration of bupivacaine may be required to safely permit the desired total injection volume of 40 mL. The epinephrine serves as a marker of intravascular injection, and the electrocardiograph should be monitored for heart rate changes. Local anesthetics containing epinephrine, 1:200,000, provide 5 µg/mL epinephrine. A 40-mL dose of local anesthetic containing epinephrine, 5 µg/mL, delivers 0.2 mg epinephrine. Adverse effects of this dose of epinephrine on some patients should be balanced against the desirability of having the epinephrine present as an indicator of intravascular injection. We do not usually see heart rate increases following TAP blocks with this dose of epinephrine, suggesting slow absorption from this fascial plane.

Optimal positioning is with the patient supine without hip or pelvic flexion. The ipsilateral arm is raised above the head to accentuate the latissimus dorsi. The lateral fat pad of obese individuals may be retracted superiorly such that the iliac crest is easily palpable in almost all cases.

The anterior iliac crest is palpated and followed posteriorly until the latissimus dorsi is detected in the midaxillary line. The iliac crest and latissimus dorsi comprise 2 sides of the Petit triangle. The border of the external abdominal oblique is not consistently palpable. A skin marker may be used to outline the site.

Aseptic technique is used throughout the block. Following skin disinfection with chlorhexidine in alcohol, the tissues of an awake patient may be locally anesthetized

with 1 to 3 mL 1% plain lidocaine using a 25-gauge 1.5-inch needle. A patient with residual spinal or epidural anesthesia will not need local anesthetic infiltration.

A 22-gauge 2-inch block needle (Braun Plexifix, Bethlehem, Pennsylvania) with syringe and tubing attached is flushed with the local anesthetic to be used. Recently my anesthesia group has switched to using 22-gauge epidural needles for TAP injections and feel this needle provides improved sense of the tissue layers.

The needle is inserted at a 90° degree angle to the skin in the middle of the Petit triangle while feeling for characteristic “pops.” There may or may not be a faint pop felt as the fascial extension of the external abdominal oblique is pierced, which may be perceived as a sensation of resistance. There should be a significant pop as the fascial plane between the external and internal abdominal obliques is entered, and there is a second similar significant pop as the fascial plane between the internal abdominal oblique and the transversus abdominis muscles is entered. This is the injection location. Needle depth is commonly 1 to 1.5 inches.

Failure to detect 2 nearly identical pop sensations approximately 1 cm apart indicates the need to reposition the needle. The needle should be withdrawn to just below skin level, the superficial tissue moved 1 cm inferiorly, and the needle advanced in this new position within the triangle. With repeated failure, the needle can be repositioned 1 cm anteriorly and the procedure can be reattempted.

Following correct positioning of the needle and negative aspiration, 20 mL of local anesthetic is injected in 5-mL increments with repeated negative aspirations and stable electrograph rhythm and heart rate. The injection is repeated on the opposite side. (Figure 3).

Discussion

In these 2 cases, TAP blocks provided effective analgesia

following cesarean delivery. In addition to TAP blocks, multimodal analgesia with nonsteroidal anti-inflammatory drugs were used. Patients reported low pain scores, and breakthrough pain was easily managed with oral acetaminophen or ibuprofen. Scheduled ketorolac appears beneficial, and this has been our broader experience. Neither patient required any of the oral or PCA narcotics available to them

Both patients breathed deeply, coughed freely, and moved without limitation. Side effects of opioids were avoided. Specifically there was no sedation, nausea, constipation, ileus, or pruritis. Early diet was completely tolerated.

Many of our regional anesthesia techniques involve placing a needle in intimate proximity to major neurological and/or vascular structures. One advantage of the TAP block is the absence of major vascular or neurological structures in this area. Literature on TAP blocks is limited. There is 1 report of liver trauma due to TAP block.⁷ In that case the block was performed before incision, and approximately 50 mL of blood was found in the abdomen during laparotomy. The source was determined to be TAP needle trauma to the liver, which was enlarged and extended to the right iliac crest. There are also 2 reports of complications involving a similar nerve block; Jöhr and Sossai⁸ report colon puncture, and Vaisman⁹ reports hematoma, both from ilioinguinal nerve blocks. It is reasonable to expect these complications would be possible with TAP blocks. Thorough familiarity with the area anatomy, safe monitoring and injection technique, and knowledge of local anesthetic pharmacology and toxicity are mandatory for safe application of any nerve block. These precautions should prevent major complications with TAP blocks.

Another risk of TAP blocks is failure. There is a subtle feel to the fascial planes when performing a TAP block. Block failure is not uncommon in the skill development phase. When TAP blocks fail, standard postoperative analgesics are used and there is no compromise of the patient's comfort.

Performing this block does not commonly require any systemic analgesia or sedation. We have performed bilateral TAP blocks in awake unsedated patients using only local lidocaine anesthesia for needle placement.

Most successful TAP block patients develop immediate and effective analgesia; however, some patients with partial analgesia continue to develop improved analgesia over the next hour or two. This delayed spread of analgesia is also reported by McDonnell and Laffey,¹⁰ who state they saw maximal spread of TAP blocks "only after several hours."

We found cesarean deliveries provide an excellent opportunity to administer this block. Successful placement of TAP blocks in a patient who may already have epidural or spinal morphine in place will still demonstrate a re-

markable improvement in analgesia. Injection in the PACU does not delay the surgeon. At that time the neonate has already been delivered and is not placed at risk. The patient may have residual spinal or epidural analgesia and will not be bothered by a needle stick. In our experience the pain following cesarean delivery is very well managed by a combination of TAP blocks and nonsteroidal anti-inflammatory drugs that are scheduled or given as needed.

Parturients are more susceptible to local anesthetic toxicity, and a reduced concentration may have to be used to limit the total dose. Although some TAP reports^{4,5} have used 0.375% levobupivacaine and found effective analgesia beyond 24 hours, my group has noted a significant improvement in both degree and duration of analgesia when we are able to use 0.5% rather than 0.375% bupivacaine with epinephrine.

Future studies could randomize a statistically large enough group of patients to compare TAP against standard PCA and neuroaxial narcotic analgesia. TAP block use in other abdominal surgeries, continuous catheter techniques, and ultrasound guidance should also be explored.

Bilateral TAP blocks provided prolonged and extremely effective analgesia, and eliminated the need for any postoperative narcotics in the cesarean delivery cases presented.

REFERENCES

1. Lubenow TR, McCarthy RJ, Ivankovich AD. Management of acute postoperative pain. In: Barish PG, Cullen BF, Stoelting RK. *Clinical Anesthesia*. 2nd ed. Philadelphia, PA: JB Lippincott; 1992:1551-1552.
2. White PF. The role of nonopioid analgesic techniques in the management of postoperative pain. In: Hadzic A. *Textbook of Regional Anesthesia and Acute Pain Management*. New York, NY: McGraw-Hill; 2007:1106.
3. Overdyk FJ, Carter R, Maddox RR, Callura J, Herrin AE, Henriquez C. Continuous oximetry/capnometry monitoring reveals frequent desaturation and bradypnea during patient-controlled analgesia. *Anesth Analg*. 2007;105(2):412-418.
4. McDonnell JG, O'Donnell B, Curley G, Heffernan A, Power C, Laffey JG. The analgesic efficacy of transversus abdominis plane block after abdominal surgery: a prospective randomized controlled trial. *Anesth Analg*. 2007;104(1):193-197.
5. O'Donnell BD, McDonnell JG, McShane AJ. The transversus abdominis plane (TAP) block in open retropubic prostatectomy [letter]. *Reg Anesth Pain Med*. 2006;31(3):91.
6. Gray H. *Gray's Anatomy*. New York, NY: Bounty Books; 1977:358-365, 778-780.
7. Farooq M, Carey MA. A case of liver trauma with a blunt regional anesthesia needle while performing transversus abdominis plane block. *Reg Anesth Pain Med*. 2008;33(3):274-275.
8. Jöhr M, Sossai R. Colonic puncture during ilioinguinal nerve block in a child. *Anesth Analg*. 1999;88(4):1051-1058.
9. Vaisman J. Pelvic hematoma after an ilioinguinal nerve block for orchialgia. *Anesth Analg*. 2001;92(4):1048-1049.
10. McDonnell BD, Laffey JG. Transversus abdominis plane block [letter]. *Anesth Analg*. 2007;105(3):883.

AUTHOR

John D. Scharine, CRNA, MSNA, APNP, is a staff anesthetist for Thedacare Physicians at Shawano Medical Center, Shawano Wisconsin. Email: scharines@charter.net.