

Preliminary Case Series Report: Use of the Laryngeal Mask Airway Fastrach Oral Endotracheal Tube With the Bullard Laryngoscope

Ken Spain, CRNA, MSED

Use of the Bullard laryngoscope has been fraught with difficulties, especially for inexperienced users who often end up placing the instrument on the back shelf of the airway cart without further use. A recent hypothesis suggests that the use of a flexible tip tube on the Bullard stylet might facilitate intubation. Initially, the Fastrach laryngeal mask airway (LMA North America, Inc, San Diego, California) flexible tip endotracheal tube was loaded on the Bullard laryngoscope stylet (Circon ACMI, Stamford, Connecticut)

and used for intubation. The ease of intubation was noteworthy. Intubations on 6 patients assessed as difficult to intubate were performed on the first attempt without any difficulty. In fact, the effortless-ness of these potentially difficult intubations led to the conclusion that the preliminary finding should be reported immediately.

Keywords: Bullard laryngoscope, Fastrach, flexible tip endotracheal tube, oral endotracheal tube.

Management of patients with difficult airways with a designated plan or algorithm has been reported, and guidelines have been established.^{1,2} Textbooks have been published to instruct anesthetists on becoming airway experts.^{3,4} Most anesthesia providers have a set plan for difficult airway management using the devices with which they are most comfortable and proficient. Many authors write about the use of multiple airway adjuncts for intubation of the trachea.⁵⁻¹²

Use of the Bullard laryngoscope has been sporadic among anesthesia providers. Many colleagues report anecdotal evidence of difficulties manipulating the scope and introducing the endotracheal tube into the glottis. Several authors have reported use of the Bullard laryngoscope, and some have compared ease of intubation with other devices such as the video-optical intubating stylet, the traditional laryngoscope, and an intubating stylet without video guidance.¹³⁻¹⁶ The purpose of this article is to share a preliminary finding of the successful use of the Bullard laryngoscope.

Technique

The hypothesis was that the use of a flexible-tipped oral endotracheal tube (OETT) would facilitate the successful intubation of patients with difficult airways using the Bullard laryngoscope. Many years of difficulties placing an OETT through the glottic opening with the Bullard laryngoscope led me to hypothesize that a flexible-tipped OETT might make the process easier; especially because one of the difficulties most often encountered involves placing the tube through the glottic opening. Using the OETT with the Fastrach laryngeal mask airway (LMA North America, Inc, San Diego, California) seemed to be worth trying and documenting. The airway itself was not used.

For the purpose of this report, a difficult airway was defined as a patient with Mallampati class III or IV rating, with limited neck flexion or extension, an overbite of 1 cm or more, or previous difficult intubation. Some patients had more than 1 contributing factor. The 6 patients involved in this study were chosen for intubation with the Bullard laryngoscope because of their airway anatomy (Table).

| | Age | Sex | ASA class | Height (ft/in) | Weight (kg) | MP class | Observed Anatomy and Comment |
|----|-----|-----|-----------|----------------|-------------|----------|--|
| 1. | 67 | F | III | 5/4 | 60 | II | No ability to extend neck |
| 2. | 45 | M | III | 6/1 | 141 | IV | Previous difficult intubation with multiple providers |
| 3. | 40 | M | II | 5/10 | 118 | III | Severe receding chin, 2 cm, overbite, micrognathia |
| 4. | 65 | F | II | 5/10 | 107 | IV | Short, thick neck, minimal neck extension, degenerative |
| 5. | 58 | M | II | 5/7 | 99 | IV | Neck totally fixed with no extension and very limited lateral mobility due to bilateral, multiple neck fusions |
| 6. | 59 | M | II | 5/8 | 99 | II | 1 cm overbite, limited extension, small receding chin |

Table. Patient Preoperative Airway Evaluation

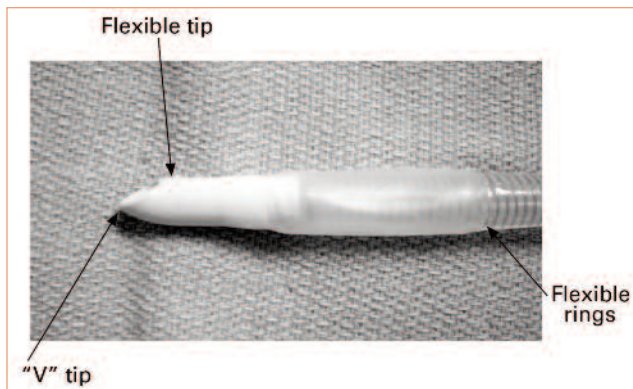


Figure 1. Flexible Tip Oral Endotracheal Tube

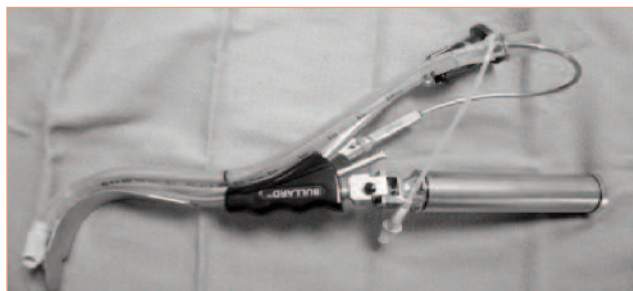

Figure 2. Flex-Tip Oral Endotracheal Tube on the Bullard Laryngoscope

The 6 patients were intubated using the Fastrach flexible tip OETT with the Bullard laryngoscope. Each intubation was visualized on the first attempt with a complete view of the vocal cords, arytenoids, and the glottic opening.

Each flexible tip endotracheal tube passed into the glottis and trachea the first time without difficulty, which is not generally the case when using the Bullard laryngoscope. Mallampati class IV patients, patients with little or no perceptible neck extension, and a patient who had a history of multiple previous attempts were intubated with equal ease. Six independent observers, including 2 CRNAs with extensive Bullard laryngoscope experience, 2 surgeons, 1 physician's assistant, and 2 experienced nurses commented on the ease with which the flexible tip OETT entered the trachea.

Why was intubation so much easier with the use of a flexible tip OETT? The "V" shaped bevel and curve of the tip facilitates passage through the glottis from all angles (Figure 1) and predisposes an easy insertion through the cords. If the OETT contacts either side of the vocal cords or glottis, the V shape enables it to glance off either side, then pass into the glottis and trachea. This is an important characteristic that enhances its use with the Bullard laryngoscope. Often, when using the Bullard laryngoscope with a traditional OETT, practitioners encounter difficulty when attempting to pass the OETT into the glottis. The flexible nature of the tip and the OETT allow




Figure 3. Tip of the Stylet and the Murphy Eye

for greater conformity and less resistance, enabling the tube to traverse a V shaped glottis and the cylindrical shape of the trachea without snagging or getting caught against the vocal cords. The traditional or common OETT is much stiffer and often gets caught against a vocal cord or the apex of the glottic opening when using the Bullard laryngoscope.

Setting up the Bullard laryngoscope was the same as with any other OETT. The stylet was lubricated with water-soluble lubricant and the flex-tip OETT was guided down the stylet with the distal end of the stylet passing through the Murphy eye of the OETT (Figure 2 and Figure 3). The cuff and the surrounding areas were also lightly lubricated and an anti-fogging agent was placed on the fiberoptic opening to prevent clouding the view.

The 6 patients were preoxygenated with 100% oxygen via mask for 4 to 5 minutes. The ability to mask ventilate was established before a muscle relaxant was administered. Each subject was given 60 mg to 100 mg of lidocaine, intravenously (IV); 100 µg of fentanyl, IV; 2 mg/kg of propofol, IV; 4 mg to 6 mg of rocuronium, IV; and 1.5 mg/kg of succinylcholine, IV, to provide adequate relaxation for intubation.

All 6 subjects were easily intubated on the first attempt with an excellent view of the flex-tip OETT passing through the glottis and into the trachea. Little to no resistance was encountered in passing the flex-tip OETT through the cords, glottis, or trachea. This was a noteworthy finding because colleagues have said that when using the Bullard laryngoscope, it is difficult to judge the amount of distal force exerted when intubating.

Conclusion

Use of the Bullard laryngoscope can be a difficult skill to master because of problems often encountered when inserting a standard OETT. Using a different OETT, a flex-tipped tube, facilitates the use of the Bullard laryngoscope with ease and success.

Patients assessed as difficult or failed intubation prospects were easily intubated on the first attempt using

the Bullard laryngoscope with the Fastrach flex-tip OETT. An important finding to note is that the flex-tipped tube also provided very little resistance sliding down the stylet, and the amount of distal force used could be sensed by the practitioner. When using a standard OETT, much resistance is encountered when the OETT is pushed down the stylet. In fact, when using the standard OETT, the force necessary to slide the OETT off the stylet and into the glottis is somewhat worrisome. The technique described in this article could improve on the safety of the instrument.

Practitioners who have placed the Bullard laryngoscope on the back shelf of the anesthesia difficult airway cart are encouraged to revisit the use of this instrument with the Fastrach flex-tip OETT.

REFERENCES

1. Henderson JJ, Popat MT, Latto IP, Pearce AC. Difficult Airway Society guidelines for the management of unanticipated difficult intubation. *Anaesthesia*. 2004;59(7):675-694.
2. Caplan RA, Benumof JL, Berry FA, et al. Practice guidelines for management of the difficult airway. A report by the American Society of Anesthesiologists Task Force on Management of the Difficult Airway. *Anesthesiology*. 1993;78(3):597-602.
3. Benumof JL. *Airway Management: Principles and Practice*. St Louis, MO: Mosby; 1996:126-142.
4. Hagberg C. *Handbook of Difficult Airway Management*. New York, NY: Churchill Livingstone; 2002:159-161.
5. Frass M, Frenzer R, Zahler J, Ilias W, Leithner C. Ventilation via the esophageal tracheal combitube in a case of difficult intubation. *J Cardiothorac Anaesth*. 1987;1(6):565-568.
6. Caponas G. Intubating laryngeal mask airway. *Anaesth Intens Care*. 2002;30(5):551-569.
7. Patil VU. *Fiberoptic Endoscopy in Anesthesia*. Chicago, IL: Yearbook Medical Publishers (now Mosby); 1983:9-15.
8. Cooper RM. Use of a new videolaryngoscope in the management of a difficult airway. *Can J Anaesth*. 2003;50(6): 611-613.
9. Kitamura T, Ydamaa Y. An efficient technique for tracheal intubation using the StyletScope alone. *Anesthesiology*. 2000;92(4):1210-1211.
10. Barriot P, Riou B. Retrograde technique for tracheal intubation in trauma patients. *Crit Care Med*. 1988;16(7):712-713.
11. Robelen GT, Shulman MS. Use of the lighted stylet for difficult intubations in adult patients [abstract]. *Anesthesiology*. 1989;71:A439.
12. Spain K. Use of the Bullard laryngoscope in the adult patient with epiglottitis: a case report. *AANA J*. 2002;70(2):127-129.
13. Weiss M, Schwarz U, Gerber A. Difficult airway management: comparison of the Bullard laryngoscope with the video-optical intubation stylet. *Can J Anaesth*. 2000;47(12):280-284.
14. Bjoraker DG. The Bullard intubating laryngoscopes. *Anesthesiol Rev*. 1990;17(5):64-70.
15. Cooper SD, Benumof JL, Ozaki GT. Evaluation of the Bullard laryngoscope using the new intubating stylet: comparison with conventional laryngoscopy. *Anesth Analg*. 1994;79(5):965-970.
16. Cohn AI, Hart RT, McGraw SR, Blass NH. The Bullard laryngoscope for emergency airway management in a morbidly obese parturient. *Anesth Analg*. 1995;81(4):872-873.

AUTHOR

Ken Spain, CRNA, MSEd, is a self-employed CRNA at Summit Surgical in Hutchinson, Kansas. Email: sandmanken@hotmail.com.